



Diabetic retinopathy screening guidelines for Physicians in India: position statement by the Research Society for the Study of Diabetes in India (RSSDI) and the Vitreoretinal Society of India (VRSI)-2023

Manisha Agarwal¹ · Padmaja Kumari Rani² · Rajiv Raman³ · Raja Narayanan² · Sreenivasamurthy L.⁴ · Anil Virmani⁵ · Ramachandan Rajalakshmi⁶ · Sudha Chandrashekar⁷ · Brij Mohan Makkar⁸ · Sanjay Agarwal^{9,10} · Mahesh Shanmugam Palanivelu¹¹ · Srinivasa Muralidhar Naveenam¹² · Kim Ramasamy¹³

Received: 13 August 2023 / Accepted: 27 November 2023
© The Author(s) 2024

Abstract

Diabetic retinopathy (DR) is a leading cause of blindness among working-age adults worldwide. India is the diabetes capital of the world and one in five adults is said to have diabetes in India. With the increase in diabetes, there is an increasing burden of diabetic retinopathy (DR). All patients with diabetes have a risk of losing vision due to DR. The prevalence of diabetic retinopathy is 12.5%; out of which, 4% are said to have vision-threatening diabetic retinopathy (VTDR). The early stages of DR are symptomless, necessitating a proactive screening for an early detection of DR in all people with diabetes before they develop VTDR. This is a position statement jointly developed by RSSDI (Research Society for the Study of Diabetes in India) and VRSI (Vitreoretinal Society of India) to provide guidelines for Physicians on DR screening in India. These guidelines emphasize the need for regular DR screening of all people with diabetes. It is recommended that the Physicians establish an effective DR screening model in their clinics, eg., a non-mydratric fundus camera utilizing artificial intelligence (AI) algorithms for fundus photography to identify referral or non-referral DR. This will facilitate early detection and timely referral to an ophthalmologist thereby preventing VTDR. The need to create public awareness regarding blindness due to DR and a collaboration between Physicians and ophthalmologists for the management of diabetes, opportunistic screening of DR, and timely management of DR may play a crucial role in decreasing the burden of blindness secondary to diabetes.

Keywords Diabetic retinopathy · Screening guidelines · Physician · India

Introduction

India has 101 million people with diabetes, and these numbers are predicted to increase to 125 million by 2045 [1, 2]. It is estimated that one in five adults will have diabetes in

India [2]. Majority are said to have type-2 diabetes during their working age impacting their work and family and causing an economic burden on the country.

Diabetes being a chronic disease has several associated systemic complications including DR which affects the

✉ Manisha Agarwal
agarwalmannii@yahoo.co.in

¹ Vitreoretina and Clinical Research, Dr. Shroff's Charity Eye Hospital, 5027 Kedar Nath Road, New Delhi 110002, India

² Anant Bajaj Retina Institute, L V Prasad Eye Institute, Hyderabad, India

³ Shri Bhagwan Mahavir Vitreoretina Services, Sanakara Nethralaya, Chennai, India

⁴ Lifecare Hospital and Research Centre, Bengaluru, India

⁵ Viru's Diabetes and Cardiac Care Centre, Jamshedpur, India

⁶ Madras Diabetes Research Foundation, Chennai, India

⁷ National Health Authority, MOHFW, GOI, New Delhi, India

⁸ Dr Makkar's Diabetes and Obesity Centre, Delhi, India

⁹ Department of Medicine and Diabetes, Ruby Hall Clinic, Pune, India

¹⁰ Department of Diabetes, Obesity and Metabolic Diseases, Sahyadri Hospitals, Pune, India

¹¹ Department of Vitreoretinal services and Ocular Oncology, Sankara Eye hospital, Bengaluru, India

¹² Vitreoretina Department, Retina Institute of Karnataka, Bengaluru, India

¹³ Vitreoretina Department, Aravind Eye Hospital, Madurai, India

vision. DR can be asymptomatic in the early stages, and if not detected and managed on time, it may progress to VTDR. The prevalence of diabetic retinopathy is 12.5%; out of which, 4% are said to have VTDR [3]. In order to timely identify patients with VTDR, we are required to actively screen all the people with diabetes. This is a huge task in a low-income country like ours where the resources are limited. Thus, there is a need for opportunistic screening for DR done at Physician clinics, which are the first point of contact for any patient with diabetes. Therefore Physicians can play an extremely important role in spreading awareness regarding various complications of diabetes including retinopathy and also do an early screening for DR. This manuscript provides guidelines for DR screening by the Physicians. The diagnosis of DR is possible with imaging and thus the various models available to the Physicians to develop the facility of DR screening in their own clinics are also highlighted.

Who are at risk of developing DR and the timing of the first screening for DR?

Individuals with diabetes are at risk of developing diabetic retinopathy (DR). The onset and progression of DR can be influenced by the duration of diabetes. It is important to note that people with type 2 diabetes may not be aware of the exact duration of their condition. Therefore, it is recommended that individuals with type 2 diabetes undergo screening for DR at the time of diagnosis.

According to the International Society of Pediatric and adolescent diabetes (ISPAD) guidelines in type 1 diabetes, it is recommended to start DR screening after 11 years of age with 2–5 years of duration of diabetes. This timeframe allows for the identification of any early signs of retinopathy [4].

For women with known diabetes who are planning to conceive, it is crucial to assess their risk of developing DR. Therefore, it is recommended that they undergo their first screening for DR prior to conception. Additionally, it is advised for these women to have a follow-up screening during the first trimester of pregnancy to monitor any changes in their retinal health.

Why patients with diabetes have to be screened for diabetic retinopathy?

Patients with diabetes should be screened for diabetic retinopathy (DR) for several important reasons. The SMART India Study was conducted in 10 Indian States and one union territory, involving over 6,000 patients with diabetes aged 40 years and above who had gradable retinal images. The study

found that 12.5% of people with diabetes had any grade of DR, and 4% had VTDR. This translates to approximately 3 million people in India who are at immediate risk of vision loss due to DR [3].

Unfortunately, the early stages of DR are asymptomatic, and once vision loss occurs, it is usually not completely reversible. Therefore, it is crucial to screen for DR after 2–5 years of type-1 and at the time of diagnosis of diabetes type-2, in order to detect it at an early stage and prevent the development of VTDR.

Role of Physicians in DR screening

Physicians have a critical role in the sensitization and screening for DR as they are usually the first healthcare providers that people with diabetes encounter. Physicians can play an extremely important role in creating awareness of the risk of vision loss due to DR. It needs to be highlighted that DR being asymptomatic in early stages may progress silently and thus the need for regular screening for DR. It is important to educate the diabetics visiting the clinic of the Physicians regarding the various complications of diabetes such as heart failure, neuropathy, nephropathy including retinopathy requiring regular screening to avoid permanent loss of vision by putting up charts, providing patient education pamphlets and having counselors in the clinic.

Patients being asymptomatic are reluctant to go to an ophthalmologist for a preventive eye check-up when they have good vision and go only when they start losing vision secondary to VTDR [3]. Physician clinics can provide an opportunistic screening for DR, just like how they would do a blood investigation for their diabetic patients. This will be a very important value addition to the services offered to the patients. This will ensure that patients having DR will be identified for an early referral and also will avoid unnecessary visits to an ophthalmologist when eyes have no evidence of DR. This will also help to reduce the unnecessary overload of patients with no DR being referred to an ophthalmologist.

DR screening guidelines for a Physician

It is important for Physicians to be aware of the screening guidelines for DR. Any patient with diabetes should undergo at least one eye exam every year irrespective of the glycemic control and the duration of diabetes [4]. The DR screening guidelines depend on the type of diabetes and the stage of DR at the time of screening (Table 1). This is based on the International clinical DR and diabetic macular edema (DME) severity scale [5]. However, the screening interval

Table 1 Diabetic retinopathy screening guidelines for a Physician

Type 1 diabetes mellitus	Initial eye examination recommended 5 years following diagnosis of type 1 diabetes mellitus
Type 2 diabetes mellitus	Initial eye examination is recommended at the time of diagnosis of type 2 diabetes mellitus
Pregnancy in patients with diabetes mellitus	<ul style="list-style-type: none"> • Eye examination prior to conception and early during 1st trimester • Follow-up should be individualized based on severity and recent changes in retinopathy
Diabetic retinopathy severity	
No apparent DR	Annual fundus photo screening at Physician clinic
Any evidence of DR or DME	Immediate referral to an ophthalmologist

DR diabetic retinopathy, DME diabetic macular edema

should be individualized based on the patient’s systemic status including glycaemic control, blood pressure, lipid levels and other comorbidities (Fig. 1).

DR screening models for Physician clinics

Developing a DR screening model at a Physician’s clinic has become easy and economical. DR diagnosis can be achieved through image analysis or AI-based algorithms which requires basic resources such as a fundus camera, a trained technician to capture high-quality retinal images, and an internet connection.

In India, options are available to enhance your skill in fundus examination and fundus photography through certified courses on DR, e.g., courses offered by Indian Health Outcomes, Public Health and Economics Research Centre (IHOPE) [6].

Screening models for diabetic clinics where there is no facility for screening to be done by an ophthalmologist

Direct ophthalmoscopy by the Physicians

Physicians and primary health care providers may use a direct ophthalmoscope (DO) for DR screening. Most of the doctors are trained in this technique during their undergraduate training [7].

Tele-screening using portable or non-portable fundus cameras

A retinal fundus camera is used to take photos of the retina through an undilated (non-mydratic) pupil that can be used to capture retinal images at Physician clinics. Details of the different types of fundus cameras available in the market utilized for DR screening are provided in Table 2. With simple

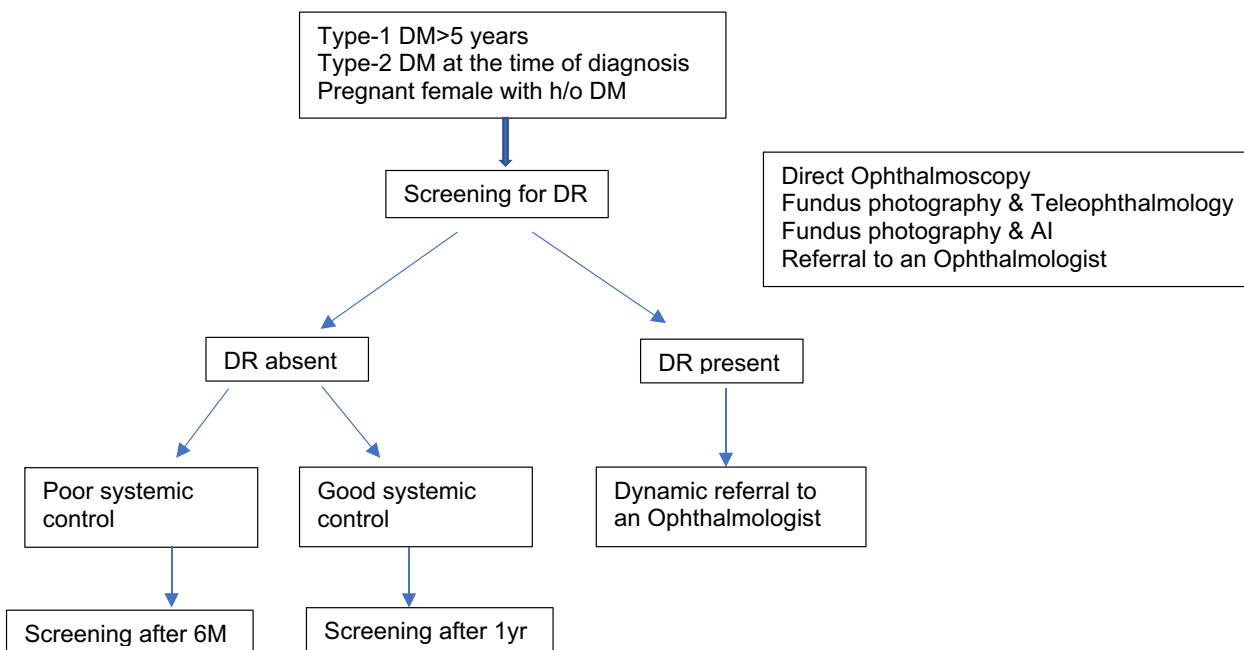


Fig. 1 Flow chart for DR screening at a Physician clinic

Table 2 Different types of Fundus cameras utilized for the DR screening

Fundus cameras	Advantage	Disadvantage
Mydriatic desktop fundus cameras	30 to 45° FOV, can cover up to 75° FOV with montage, stereo images of various fields, excellent resolution, seven-field stereo photography, easy to use with training, good image quality, good for hospital usage, better sensitivity and specificity for detecting DR by ETDRS fundus photograph grading than DO or IDO exam	Requires mydriasis, expensive, time-consuming procedure for training photographers and graders
Commercially available cameras	Carl Zeiss FF 450 plus, 3 Nethra-Forus (Model: Flora)	Ungradable photographs and low sensitivity particularly in Indian eyes with dark iris, in cases of cataract or small pupil size
Non-mydriatic Fundus camera	45° FOV, Autofocus, auto alignment, user interface software, task automation, storage of images, and export of images to database and facility to share retinal images through a network or internet connection.	
Commercially available	Zeiss Cirrus 600, Crystal Vue NFC-700, 3 Nethra-Forus (Model: Classic), Canon CR-2 & AF, Centre Vue DRS, Topcon TRC NW 400, AFC-230, Nidek, gamagori, Japan	
Ultra-wide field Fundus camera	Very wide field of view up to 200° without dilatation, can detect peripheral DR lesions	Very expensive, cannot be used for mass screening unless the cost gets reduced
Commercially available	Optos, Optomap/Daytona Staurenghi lens (Ocular Staurenghi 230 SLO Retina Lens), Ocular Instruments Inc, Bellevue, WA, USA) Pomerantzef camera, Retcam (Clarity Medical Systems, Inc., Plea santon, CA, USA), ZEISS Clarus 500 (Zeiss, Carl Zeiss Meditech, Inc., Dublin, USA)	
Handheld	Handheld digital cameras are portable, require less space, minimum power consumption and less skills and training	Image quality may be inferior without mydriasis, especially for older people with cataracts
Commercially available cameras	Zeiss Visuscout 100 (Carl Zeiss, Jena, Germany), Smartscope Pro (Optomed, Oulu, Finland) Volk Pictor Plus (Volk Optical, Mentor, OH, USA), VersaCam TM DS-10 (Nidek, Gamagori, Japan), Horus DEC 200 (MiiS, Hsinchu, Taiwan), Genesis-D (Kowa, Nagoya, Japan) and Optomed Aurora	
Smartphone-based fundus camera	Smartphones are universally available and these smartphone-based fundus cameras are cost-effective alternative options for traditional fundus cameras.	Require mydriasis
Remidio fundus on phone (FOP)(Remidio Innovative Solutions,Bangalore,India)	US FDA-approved validated retinal imaging system, mydriatic and non-mydriatic and anterior imaging module, 45° FOV (M) with \pm 20D adjustment with 12x optical magnification, 40° FOV (NM) and 10X magnification, Tabletop model or handheld mode and can also be attached to a smartphone	
Made in India retinal camera(MII Retcam, India)	Capable of visualizing even peripheral regions of the retina up to pars plana along with the posterior pole, provides video and still image	Require mydriasis
Other Smartphone-based validated fundus cameras are available	Peek Retina(Nesta, London, UK), PanOptic + iExaminer (Welch Alllyn, Skaneateles Falls, NY), D-EYE, Padova, Italy	Peek vision device requires mydriasis, PanOptic and D-Eye and have limited FOV 25° and 20

training, any clinic assistant or optometrist (if available) can capture retinal images using these fundus cameras. These images can be stored and forwarded online to remote ophthalmologists or trained graders (today very few are available) [8]. The retina specialist will review the images, grade them for DR severity and generate a report to be sent back to the Physician's office. This whole process may take a few hours to a few days depending on the resources available (Fig. 2).

Tele-screening using portable or non-portable fundus cameras using AI

Artificial Intelligence (AI) is playing a major role in DR screening. AI is able to grade the retinal images equivalent to a retina specialist and can identify referable DR and not referable DR. More importantly, it can grade and generate a report almost instantaneously. The patient will be able to get his eye report within a few minutes and the Physician can advise the patient accordingly [9].

The sensitivity and specificity of a few commercial automated DR grading software are given in Table 3 [10–13].

The report is provided to the patient along with a disclaimer that it is a screening test with a specific sensitivity and specificity and cannot be used for any medicolegal purpose. The main purpose of the screening test and the automated report is to alert the patients in case any evidence of DR is found so that he or she can be timely referred for a detailed evaluation and further management by an ophthalmologist. This may ensure better compliance for DR screening and reduce the risk of vision loss due to DR.

Physician clinics with an ophthalmology referral facility can ensure timely diagnosis and management of DR.

DR screening as a part of diabetes care

- Incorporation of DR screening as a standard of care for diabetes with regular referral to an ophthalmologist for DR screening.

- The second option is that instead of sending every patient to the Ophthalmologist for DR screening, an in-clinic screening can be done using a fundus camera with AI or without AI using teleophthalmology.
- If the patient has a referral DR, then is sent for further evaluation and management to the in-house ophthalmologist.

Community-based DR screening

DR screening during diabetes screening

Non-Governmental Organizations (NGOs), diabetic clinics and corporate offices conduct annual health check-up programs or diabetes screening programs annually [14]. DR screening can be included as a part of the package. These days, corporate screening programs are also implemented in offices where a sedentary lifestyle and work stress increase the risk of diabetes and DR at a younger age, and these camps can help in opportunistic screening for DR.

Risk-based DR screening

Risk-based screening (age, duration of diabetes, blood sugar levels, cholesterol levels, blood pressure levels) would be feasible, cost-effective, and safe, and the screening can be individualized based on the risk score.

The All India Ophthalmological Society (AIOS) task force committee and Vitreo Retinal Society India (VRSI) recommends diabetic retinopathy (DR) screening for individuals with known diabetes who are receiving treatment and have a random blood sugar (RBS) level of ≥ 200 mg/dl (≥ 11.1 mmol/l), or have glycosylated hemoglobin (HbA1C) levels of $> 6.5\%$ (48 mmol/l). Screening is also necessary for females with type-1 diabetes and gestational diabetes when they first report to a healthcare provider [15].

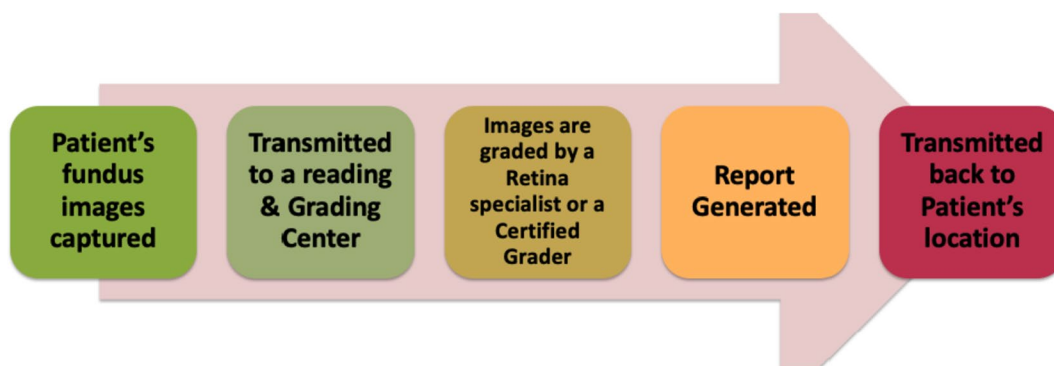


Fig. 2 DR screening using Teleophthalmology

Table 3 Sensitivity and Specificity of the commercial automated DR grading algorithms

Few commercial automated DR grading software	Fundus images involved	Sensitivity and specificity
IDx-DR with Topcon Fundus camera (US FDA-approved AI algorithm, on April 2018)	819 participants' fundus images	The sensitivity and specificity of the technology were 87.2% and 90.7% respectively for detecting more than mild DR.
Retmarker	102,856 fundus images	Compared to arbitrated human grading results. The sensitivity for retmarker in detecting DR was 73.0% for any retinopathy, 85.0% for referable retinopathy and 97.9% for proliferative retinopathy, and false positive rate was 47%.
EyeArt (Eyenuk Inc., based in Los Angeles, USA), (US FDA approved in 2020)	A total of 915 participants' fundus images	96% sensitivity and 88% specificity for detecting mild DR and 92% sensitivity and 94% specificity for detecting vision-threatening DR
Google AI (Google Inc.)	Training-103,634 images Validation of 5764 images from both sites	In INDIA, two centers dataset was used: Sankara Nethralaya Sensitivity, 92.1%; Specificity, 95.2%; AUC, 0.980; Aravind Eye Hospital Sensitivity, 88.9%; Specificity, 92.2%; AUC, 0.963

PM-JAY DR guidelines for a Physician

Ayushman Bharat Pradhan Mantri Jan Arogya Yojana (AB PM-JAY) is a Centre and state co-sponsored health insurance/assurance scheme providing healthcare services as per predefined packages to about 500 million population based on specific eligibility. This scheme is implemented by the National Health Authority (NHA) in partnership with state health agencies through 28,000 empaneled facilities (both government and private) across India except 3 states (Delhi, West Bengal, and Odisha).

In April 2022, NHA released the HBP 2022 which includes the DR screening package including—refraction, fundus photo and optical coherence tomography (OCT). This package has a cross-speciality model with reimbursement applicable to screening both by a Physician and an ophthalmologist [16].

Role of metabolic control in the management of DR

Good metabolic control including blood sugar level, blood pressure and dyslipidemia retards the progression of DR

- Higher initial levels of HbA1c increase the risk of DR. Intensive glycemic control (HbA1c < 7%), especially in the early stages of onset of diabetes, has a profound impact on the progression of DR and reduces the risk of developing DR by 27% [17].
- Control of high lipids reduced the risk of developing hard exudates and decrease the associated vision loss [18].

- In type-2, there is a decrease in DR by 31% for every 1% decrease in HbA1c and a decrease in vitreous hemorrhage by 11% for every 10 mmHg decrease in systolic blood pressure [19]. It is recommended that diabetics with hypertension regularly monitor their blood pressure and keep it below 140/80 mm Hg.

Quality assurance standards for DR screening

Quality assurance should be a part of any DR screening program in order to achieve maximum benefit [20].

1. Informed consent before capturing the retinal images
2. A good quality, affordable, sleek, easy-to-operate fundus camera that can provide high-resolution images with a wide field of view (130–200°) would be ideal.
3. Two images of the retina per eye (one macula-centered and one optic disc-centered image) would be useful to ensure that DR is not missed. An additional image of the anterior segment of the eye would provide additional information regarding media opacity/cataract.
4. Although non-mydriatic fundus cameras are used for screening, mydriasis using dilatation eye drops improves the gradeability of the images and reduces the number of ungradable images.
5. The grading of the retinal images should be done by certified human graders.
6. AI software used should be validated and approved for DR detection [21]. A disclaimer should be there with the report that it is a screening test and not for medicolegal purposes. AI grading of DR can be utilized as

an assistive tool, with the final grading of DR to be determined by a doctor.

7. The DR screening reports should be promptly available to the patient when having a follow-up check-up with the Physician to ensure a timely referral to an ophthalmologist.
8. Proper backup and storage of the retinal images and DR diagnosis data is essential for follow-up. Preferable if there is an inbuilt alert system in case a patient misses his or her screening visit.
9. There should be a recall system where individuals with diabetes who have been screened the previous year are called back for DR screening/retinal imaging through a reminder call/SMS.

Creating public awareness for DR

Every opportunity should be used to spread awareness of blindness due to DR. A Physician should insist on the report of DR screening at the time of consultation. Patient education posters in patient waiting areas and pamphlets with pictures can help spread awareness about DR. DR screening should become a part of the standard of care for diabetes.

Summary of the position statement

- Any individual with diabetes is susceptible to developing DR and the onset is earlier in those with the risk factors
- The occurrence of DR is influenced by the duration of diabetes, applicable to both type-1 and 2 diabetes.
- The initial stages of DR are symptomless, necessitating proactive annual screenings for early detection in all diabetes patients.
- Advanced stages of DR can lead to irreversible vision loss, and despite the advanced treatment procedures, including complex vitreoretinal surgeries, the visual prognosis may remain poor.
- Optimal management of systemic factors like blood sugar, blood pressure, and lipid profile (LDL cholesterol < 70 mg%) is pivotal in slowing down DR progression.
- Physicians, as the primary healthcare providers for diabetes patients, have a vital role in raising awareness about DR.
- Physicians should establish an effective DR screening program in their clinics, facilitating early detection, timely referrals to ophthalmologists, and prevention of VTDR.
- Non-mydratic cameras utilizing AI algorithms in fundus photography can aid in identifying referral or non-referral cases of DR.
- Collaboration between Physicians and ophthalmologists is imperative in the screening process for DR in diabetes patients.

- Public awareness campaigns through clinic posters, patient education materials, and media initiatives can enhance understanding of the risks of blindness associated with DR.

Conclusion

India faces a significant burden of diabetes, resulting in a rise in diabetic retinopathy (DR) cases and preventable blindness. Lack of awareness and asymptomatic early stages of DR contribute to patients not seeking eye screenings, leading to the development of VTDR and permanent vision loss.

In conclusion, the position statement by RSSDI and VRSI serves as a crucial guide for fostering collaboration between Physicians and ophthalmologists in India. By working together, they can effectively combat the burden of diabetic retinopathy (DR) and prevent unnecessary blindness. The statement emphasizes the importance of raising awareness, implementing early screening measures and utilizing cost-effective models to detect and manage DR at its early stages. Through this collaborative effort, we can strive towards a future where preventable blindness due to DR becomes a rarity in India.

Open Access This article is licensed under a Creative Commons Attribution 4.0 International License, which permits use, sharing, adaptation, distribution and reproduction in any medium or format, as long as you give appropriate credit to the original author(s) and the source, provide a link to the Creative Commons licence, and indicate if changes were made. The images or other third party material in this article are included in the article's Creative Commons licence, unless indicated otherwise in a credit line to the material. If material is not included in the article's Creative Commons licence and your intended use is not permitted by statutory regulation or exceeds the permitted use, you will need to obtain permission directly from the copyright holder. To view a copy of this licence, visit <http://creativecommons.org/licenses/by/4.0/>.

References

1. Anjana RM, Unnikrishnan R, Deepa M, Pradeepa R, Tandon N, Das AK, Joshi S, Bajaj S, Jabbar PK, Das HK, Kumar A. Metabolic non-communicable disease health report of India: the ICMR-INDIAB national cross-sectional study (ICMR-INDIAB-17). *Lancet Diabetes Endocrinol.* 2023. [https://doi.org/10.1016/S2213-8587\(23\)00119-5](https://doi.org/10.1016/S2213-8587(23)00119-5).
2. IDF diabetes atlas, tenth edition. International Diabetes Federation. 2021. <https://diabetesatlas.org/>. Accessed 11 July 2023
3. Raman R, Vasconcelos JC, Rajalakshmi R, Prevost AT, Ramasamy K, Mohan V, Mohan D, Rani PK, Conroy D, Das T, Sivaprasad S. Prevalence of diabetic retinopathy in India stratified by known and undiagnosed diabetes, urban–rural locations, and socioeconomic indices: results from the SMART India population-based cross-sectional screening study. *Lancet Glob Health.* 2022;10(12):e1764-73. [https://doi.org/10.1016/S2214-109X\(22\)00411-9](https://doi.org/10.1016/S2214-109X(22)00411-9).
4. Bjornstad P, Dart A, Donaghue KC, Dost A, Feldman EL, Tan GS, Wadwa RP, Zabeen B, Macovecchio ML. ISPAD clinical practice consensus guidelines 2022: microvascular and macrovascular

- complications in children and adolescents with diabetes. *Pediatr Diabetes*. 2022;23:1432–50.
5. Wilkinson CP, Ferris FL III, Klein RE, Lee PP, Agardh CD, Davis M, Dills D, Kampik A, Pararajasegaram R, Verdaguer JT. Global Diabetic Retinopathy Project Group Proposed international clinical diabetic retinopathy and diabetic macular edema disease severity scales. *Ophthalmology*. 2003;110(9):1677–82.
 6. IHOPE 2020 Grading of diabetic retinopathy and diabetic macular edema, 2022. <https://ihope2020.org/diabetic-retinopathy/>. Accessed 23 Dec 2023
 7. Venkatesh P. Compulsory training in ophthalmology as part of undergraduate general medicine training: need of the hour. *Nat Med J India*. 2018;31(5):306.
 8. Rajalakshmi R, Prathiba V, Arulmalar S, Usha M. Review of retinal cameras for global coverage of diabetic retinopathy screening. *Eye*. 2021;35(1):162–72. <https://doi.org/10.1038/s41433-020-01262-7>.
 9. Li JP, Liu H, Ting DS, Jeon S, Chan RP, Kim JE, Sim DA, Thomas PB, Lin H, Chen Y, Sakamoto T. Digital technology, telemedicine and artificial intelligence in ophthalmology: a global perspective. *Prog Retin Eye Res*. 2021;1(82):100900. <https://doi.org/10.1016/j.preteyeres.2020.100900>.
 10. Abràmoff MD, Lou Y, Erginay A, Clarida W, Amelon R, Folk JC, Niemeijer M. Improved automated detection of diabetic retinopathy on a publicly available dataset through integration of deep learning. *Invest Ophthalmol Vis Sci*. 2016;57(13):5200–6. <https://doi.org/10.1167/iovs.16-19964>.
 11. Tufail A, Kapetanakis VV, Salas-Vega S, Egan C, Rudisill C, Owen CG, Lee A, Louw V, Anderson J, Liew G, Bolter L. An observational study to assess if automated diabetic retinopathy image assessment software can replace one or more steps of manual imaging grading and to determine their cost-effectiveness. *Health Technol Assess*. 2016;20(92):1–72.
 12. Ipp E, Liljenquist D, Bode B, Shah VN, Silverstein S, Regillo CD, Lim JJ, Sadda S, Domalpally A, Gray G, Bhaskaranand M. Pivotal evaluation of an artificial intelligence system for autonomous detection of referable and vision-threatening diabetic retinopathy. *JAMA Netw Open*. 2021;4(11):e2134254. <https://doi.org/10.1001/jamanetworkopen.2021.34254>.
 13. Gulshan V, Rajan RP, Widner K, Wu D, Wubbels P, Rhodes T, Whitehouse K, Coram M, Corrado G, Ramasamy K, Raman R. Performance of a deep-learning algorithm vs manual grading for detecting diabetic retinopathy in India. *JAMA Ophthalmol*. 2019;137(9):987–93. <https://doi.org/10.1001/jamaophthalmol.2019.2004>.
 14. Sivaprasad S, Raman R, Rajalakshmi R, Mohan V, Deepa M, Das T, Ramasamy K, Prevost AT, Wittenberg R, Netuveli G, Lingam G. Protocol on a multicentre statistical and economic modelling study of risk-based stratified and personalised screening for diabetes and its complications in India (SMART India). *BMJ Open*. 2020;10(12):e039657. <https://doi.org/10.1136/bmjopen-2020-039657>.
 15. Raman R, Ramasamy K, Rajalakshmi R, Sivaprasad S, Natarajan S. Diabetic retinopathy screening guidelines in India: all India ophthalmological society diabetic retinopathy task force and vitreoretinal society of India consensus statement. *Indian J Ophthalmol*. 2021;69(3):678. https://doi.org/10.4103/ijo.ijo_667_20.
 16. Government of India Ministry of Health and Family Welfare (National Health Authority) AB-PMJAY Health Benefit Package Master 2022. <https://pmjay.gov.in/sites/default/files/2022-04/HBP%202022%20..pdf>
 17. Diabetes Control and Complications Trial Research Group. The relationship of glycemic exposure (HbA1c) to the risk of development and progression of retinopathy in the diabetes control and complications trial. *Diabetes*. 1995;44(8):968–83. <https://doi.org/10.2337/diab.44.8.968>.
 18. Rodriguez-Fontal M, Kerrison JB, Alfaro DV, Jablon EP. Metabolic control and diabetic retinopathy. *Curr Diabetes Rev*. 2009;5(1):3–7. <https://doi.org/10.2174/157339909787314176>.
 19. Kohner EM. Microvascular disease: what does the UKPDS tell us about diabetic retinopathy? *Diabetic Med*. 2008;25:20–4. <https://doi.org/10.1111/j.1464-5491.2008.02505.x>.
 20. Schneider S, Aldington SJ, Kohner EM, Luzio S, Owens DR, Schmidt V, Schuell H, Zahlmann G. Quality assurance for diabetic retinopathy telecreening. *Diabetic medicine*. 2005;22(6):794–802. <https://doi.org/10.1111/j.1464-5491.2005.01512.x>.
 21. Padhy SK, Takkar B, Chawla R, Kumar A. Artificial intelligence in diabetic retinopathy: a natural step to the future. *Indian J Ophthalmol*. 2019;67(7):1004. https://doi.org/10.4103/ijo.IJO_1989_18.

Publisher's Note Springer Nature remains neutral with regard to jurisdictional claims in published maps and institutional affiliations.